

Kelly (H. A.)

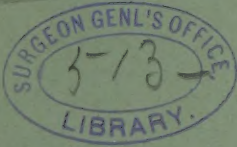
The Advantage of Atmospheric
Distention of the Rectum, with
Dislodgment of the Small In-
testines, in the Bimanual Ex-
amination of Uterus, Ovaries,
and Tubes.

BY
HOWARD A. KELLY, M.D.
Baltimore, Md.

REPRINTED FROM
THE AMERICAN JOURNAL OF OBSTETRICS
Vol. XXIX., No. 5, 1894.

NEW YORK
WILLIAM WOOD & COMPANY, PUBLISHERS
1894

presented by the author



THE ADVANTAGE OF ATMOSPHERIC DISTENTION OF THE
RECTUM, WITH DISLODGMET OF THE SMALL INTESTINES,
IN THE BIMANUAL EXAMINATION OF UTERUS,
OVARIES, AND TUBES.


I HAVE on several previous occasions drawn attention to important modifications of the ordinary bimanual examination—such as a deep invagination of the pelvic floor in making the pelvic organs more accessible—the bimanual examination by abdomen and rectum, assisted by simultaneous traction upon the cervix with corrugated tenaculum or tenaculum forceps, called for this reason “trimanual examination,” thus producing an artificial retroposition and descensus uteri,¹ as well as the possibility of throwing the fundus into an artificial sharp retroflexion and examining the anterior face of the uterus by means of the finger in the rectum.²

In spite, however, of these unusual facilities for investigation, cases present themselves from time to time in which the broad-ligament structures can only be detected and outlined with considerable difficulty, and only after a patient persistence in seeking them out. Not that the finger can find nothing in the pelvis; on the contrary, it is embarrassed by finding too much, for the touch is constantly impeded in the course of the examination by the viscera which crowd down into the pelvis from above, forming a sort of pelvic enterocele. Some impairment of the tactile sense is also experienced from the constant contact of the finger with the rectal mucous folds.

Coils of small intestines in the pelvis containing fluid often feel tense and fluctuating, and thus readily impose themselves upon the examiner as large cystic ovaries, or leave him in doubt as to their true nature.

¹ AMERICAN JOURNAL OF OBSTETRICS, February, 1891.

² New York Medical Journal, November 25th, 1893, and Annals of Gynecology and Pediatrics, January, 1894.



The complete removal of these impediments may be satisfactorily effected in the following manner: The patient is placed in the knee-breast posture, with shoulders on the table and hips high and thighs vertical. The anal orifice is opened by a small

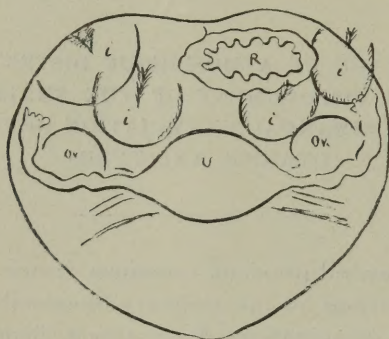


FIG. 1 shows the relations of the collapsed rectum (R) to uterus (U) and ovaries (Ov), the small intestines (i, i) filling the pelvis.

speculum or tube, allowing the air to rush into the rectum. The explanation of this phenomenon is that, upon assuming the knee-breast posture, the small intestines gravitate along the anterior

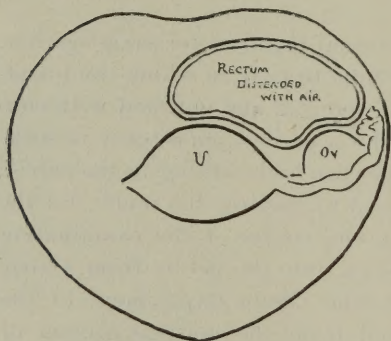


FIG. 2.

FIG. 2 shows the relations of the bowel distended with air to uterus and ovary after the small intestines have been displaced.

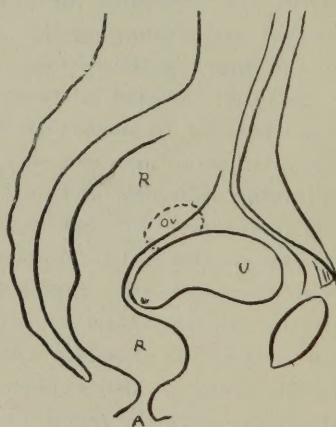


FIG. 3.

FIG. 3 shows the facility with which the digital examination can be made through the rectum thus distended and applying itself widely to the posterior surface of the uterus and broad ligament.

abdominal wall into the upper abdomen toward the diaphragm, creating a suction at the most elevated portion, which is the

pelvic extremity, by means of which the whole ampulla and rectum balloon out with air as soon as the anus is opened, and the distended rectum applies itself broadly over the posterior surface of the uterus and left broad ligament.

Before making such an examination both rectum and bladder should be thoroughly evacuated. The pelvis being thus elevated, as soon as the atmospheric dilatation is effected the tube is removed, the anus closes, and the patient is placed in the dorsal position with thighs flexed upon the abdomen, and the bimanual examination is at once made per rectum and abdomen.

The index finger coated with vaselin, introduced within the anus, experiences at once the remarkable sensation of entering a large cavity filled with air, in which the customary resistance is absent. The communication with the upper bowel between the utero-sacral folds is, under these circumstances, readily found, and the finger is conducted behind the broad ligament, when, on using the outside hand in assistance, uterus, broad ligaments, ovaries, and tubes are at once palpated directly through the rectal wall, without resistance and with startling distinctness.

The true pelvic viscera thus seem, as it were, to be skeletonized in the pelvis, lying so clearly exposed to touch that the minuter surface peculiarities, fissures and elevations, and changes in consistence, can be detected, and a diagnosis made more satisfactorily, more rapidly, and with far less effort than under ordinary conditions.

905 NORTH CHARLES STREET.

